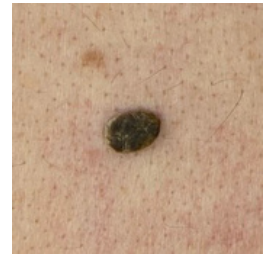


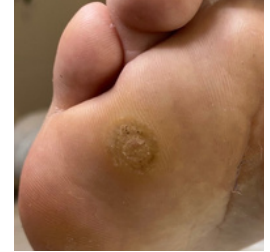Seborrhoeic keratosis

These are very common on the head, face, neck, back and limbs and mainly arise with increasing age and sun damage. They can grow up to two inches wide and are often dry and crusty.



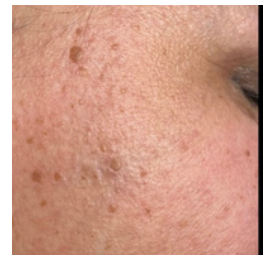Verruca

Also known as a plantar wart is a wart on the sole of the foot. They can be speckled with black dots and they can vary in size. They can become really tender and painful to walk on. They are notoriously resilient to methods of removal, but diathermy is a safe and effective way to treat them.



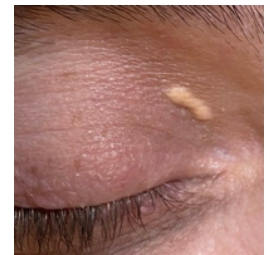Dermatosis papulosa nigra (DPN)

This is a common disorder that often develops on black skin. They are dome shaped, brown to black papules. Found commonly on cheeks, neck and upper chest.



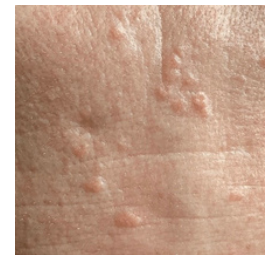Xanthelasma palpebrarum

Blemishes caused by deposits of cholesterol under the surface of the skin. Often found on the upper and lower eyelids. The nature of these blemishes make them hard to disguise or camouflage with make up.



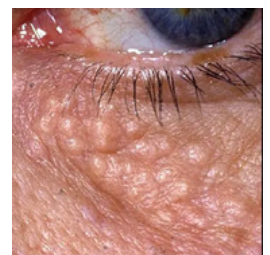
Sebaceous hyperplasia

These are an inflammation of the sebaceous glands in adults. They manifest as yellowish, soft, small papules on the face.



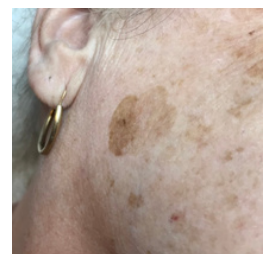Syringoma

Non contagious flesh coloured elevations of the skin, often found beneath the eyes.



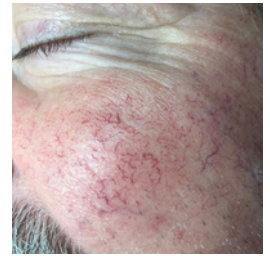Age/Sun spots

These are flat, pigmented blemishes located in areas most exposed to the sun.



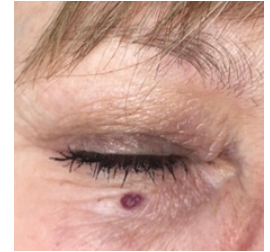Facial red veins

Facial red veins are permanent dilation of capillaries that are visible under the skin. There are many causes including ageing, alcohol, childbirth, diabetes, diet, high blood pressure, physical trauma to name a few. There is a 60-80% improvement in the appearance of facial red veins when treated with diathermy.



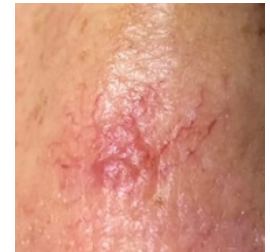Cherry Angioma/Blood spots

Bright red, superficial and circular vascular blemishes. They are often dome shaped or slightly raised and are frequently found on the midriff.



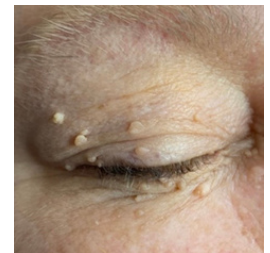
Spider Naevi

Consists of a central dilated blood vessel, with smaller capillaries radiating from it like legs of a spider. They can be found in isolation or gathered together in clumps on areas such as the cheeks.



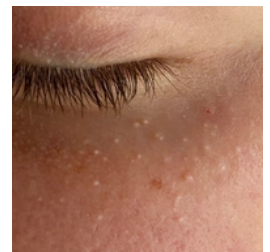Skin tags

Skin tags are mainly found in areas of friction such as the underarm, groin, under the breasts or around the neck where necklaces and collars irritate. They often appear with a stalk attachment.



Milia

These are tiny white hard round spots which lie superficially under the skin which contain keratin.



Warts

Warts are small, rough, viral growths on the skin. They are very common and are usually spread by direct skin to skin contact or indirectly through shared contact with contaminated surface. There are various types of warts including plane, common and filiform.

